

# Peptic Ulcer Disease

Dr Rodney Itaki



**DIVISION OF PATHOLOGY**

**School of Medicine & Health Sciences**

UNIVERSITY OF PAPUA NEW GUINEA

# Peptic Ulcer

- Chronic Peptic Ulcer
- Acute Peptic Ulceration

Chronic Peptic Ulcer

# **PEPTIC ULCER DISEASE**

# Overview

- Peptic Ulcer – breach in the mucosa extending from muscularis mucosae into submucosa or deeper
- Can occur anywhere in GIT but more commoner in duodenum & stomach
- Acute gastric ulcer can occur from severe systemic stress e.g. Stress ulcers from severe infection

# Peptic Ulcer

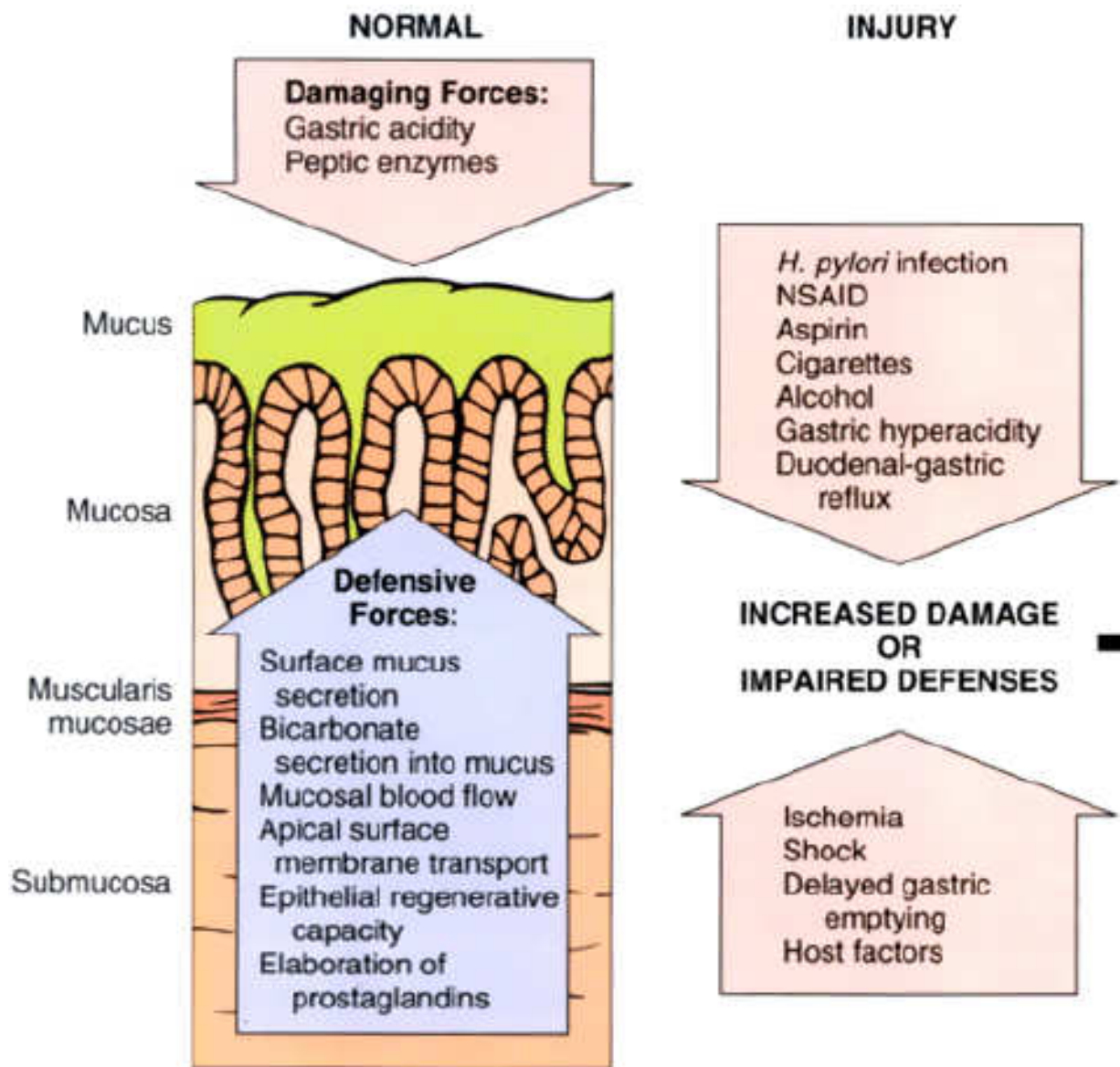
- Chronic – long history
- Solitary – single.
- Site – along GIT exposed to action of acid-peptic juices
- Site of occurrence:
  - Duodenum – first portion
  - Stomach – antrum
  - Gastroesophageal junction – setting of reflux
  - Within margins of a gastrojejunostomy
  - Duodenum, stomach or jejunum in pts with ZE syndrome
  - Within or adjacent to Meckel diverticulum – ectopic gastric mucosa

# Epidermiology

- 350,000 new cases diagnosed per year in US (2000)
- PNG Data unknown but is a common clinical presentation
- Lifetime risk in developing ulcer
  - 10% male & 4% females (US figures)
- Remitting & relapsing lesions – chronic history.
- More common in middle-aged to older individuals.
- Women more affected at or after menopause

# Pathogenesis

- Imbalance between mucosal defence mechanisms & damaging forces
- Gastric acid & pepsin must be present
- Hyperacidity is NOT a prerequisite
- Only minority of pts with peptic ulcer have hyperacidity
- *H.pylori* infection is known to cause peptic ulcer
  - All pts with duodenal ulcers have *H.pylori* infection
  - 70% of pts with gastric ulcers have *H.pylori* infection





# Pathogenesis

- Peptic ulcer can readily occur:
  - Mucosal blood flow drops – hypovolumic shock
  - Gastric emptying is delayed
  - Epithelial restitution is impaired

# *H. Pylori* & Peptic Ulcer Pathogenesis

- Urease generates free ammonia & a protease breaks down glycoproteins in gastric mucus
- Phospholipases which damage epithelial cells
- Neutrophils release myeloperoxidase which produces hypochlorous & monochloramine that destroy cells
- Mucosal epithelial cells & lamina propria endothelial cells are targets for destructions of *H.pylori* during colonisation.

# *H. Pylori* & Peptic Ulcer Pathogenesis

- Surface capillaries are also thrombosed. This is promoted by bacterial platelet-activating factor
- Elaboration of other enzymes result in chronic inflammation. Chronically inflamed mucosa more susceptible to acid injury
- Damage in mucosa allows leakage of nutrients into surface microenvironment sustaining the bacillus

# Pathogenesis

- Only 10-20% of individuals with *H.pylori* infection develop peptic ulcer.
  - Why some do & other do not?
- Actual infection limited to stomach but pts develop duodenal ulcer. Why?
  - Some studies suggest ammonia stimulates gastrin release thereby increasing acid production
- Link between *H.pylori* & peptic ulcer is established but interactions leading to ulceration remains to be elucidated.

# Hyperacidity & Peptic Ulcer Pathogenesis

- Gastric hyperacidity is strongly ulcerogenic
- Causes of hyperacidity:
  - Increased parietal cell mass
  - Increased sensitivity to secretory stimuli
  - Increased basal secretory drive
  - Impaired inhibition of stimulatory mechanisms such as gastrin release
- In ZE syndrome there is excess gastrin secretion from gastrin secreting tumor resulting in increased acid production
  - ZE exhibits multiple ulcers in stomach, duodenum & jejunum

# Peptic Ulcer Pathogenesis

- Chronic NSAIDS use suppress mucosal prostaglandin synthesis
- Cigarette smoking impairs mucosal blood flow & healing
- Alcoholic cirrhosis is associated with increased incidence of peptic ulcers
- Rapid gastric emptying exposes mucosa to excessive acid load

# Peptic Ulcer Pathogenesis

- Duodenal ulcers more frequent in pts with:
  - Alcoholic cirrhosis
  - COPD
- Chronic Renal Failure – hypercalcaemia stimulates gastrin production thereby increased acid production
- Hyperparathyroidism – hypercalcaemia stimulates gastrin production thereby increased acid production
- Genetic influences appear to play no role.

# Peptic Ulcer Pathogenesis

- Personality traits
- Psychological stress
- Spices
- Fizzy drinks (carbonated soft drinks)
  
- Compelling arguments but no hard evidence to suggest these factors have role in peptic ulcer pathogenesis



# Morphology

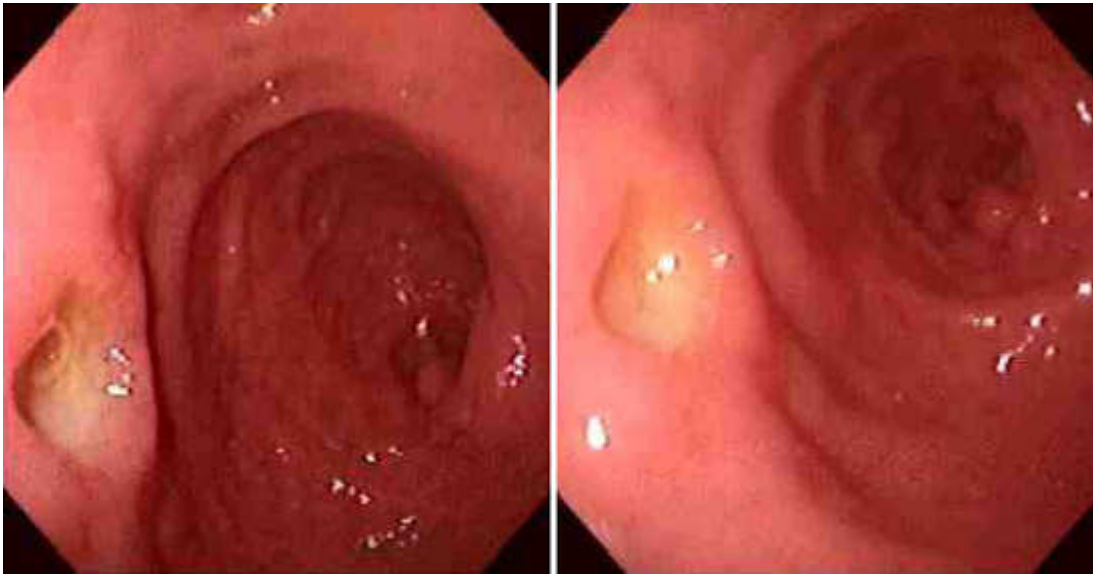- 98% occur in duodenum or stomach in a ratio of 4:1.
- Gastric ulcers – occur along lesser curvature
- 80-90% pts have single ulcer but
  - 10-20% have gastric & duodenal ulcer
- Small lesions (<0.3cm) are shallow erosions
- Lesions >0.6cm are bona fide ulcers
- 50% of ulcers are <2cm in diameter but larger ulcers (>4cm) do occur
- **Size does not differentiate a benign from a malignant ulcer**

# Morphology

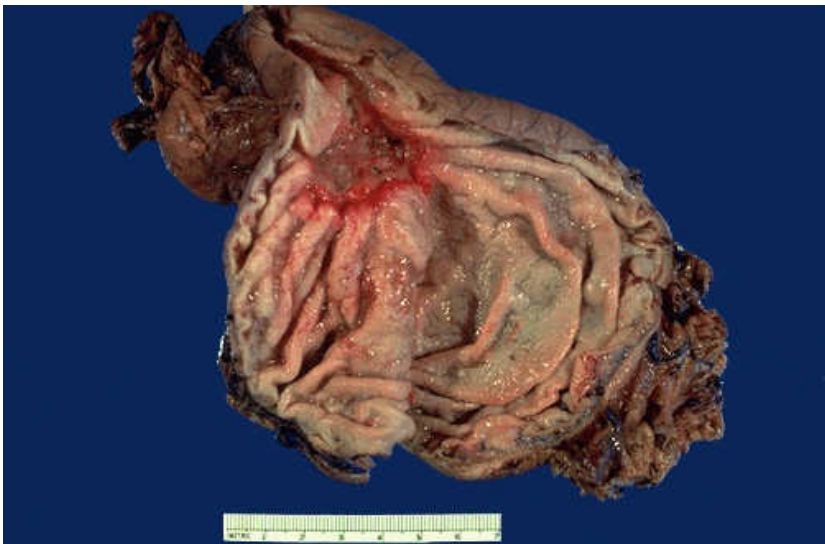- Classic peptic ulcer – round to oval sharply punched out defect with straight walls and clean base.
- Depth is variable depending on chronicity of ulcer presence and ongoing acute & chronic inflammation.
- Involves mucosa or extending to muscularis propria
- If perforation occur pancreas, omental fat or liver can form the base

# Morphology

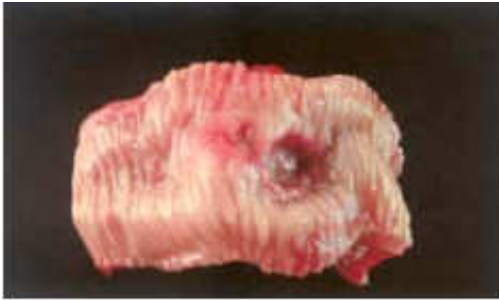- Base of ulcer is clean and smooth – peptic digestion of exudate & debris
- Scarring may occur and involve entire thickness of stomach
  - Puckering of surrounding mucosa creates mucosal folds radiating from the ulcer crater in a spokelike fashion
- Surrounding mucosa is oedematous & reddened due to gastritis



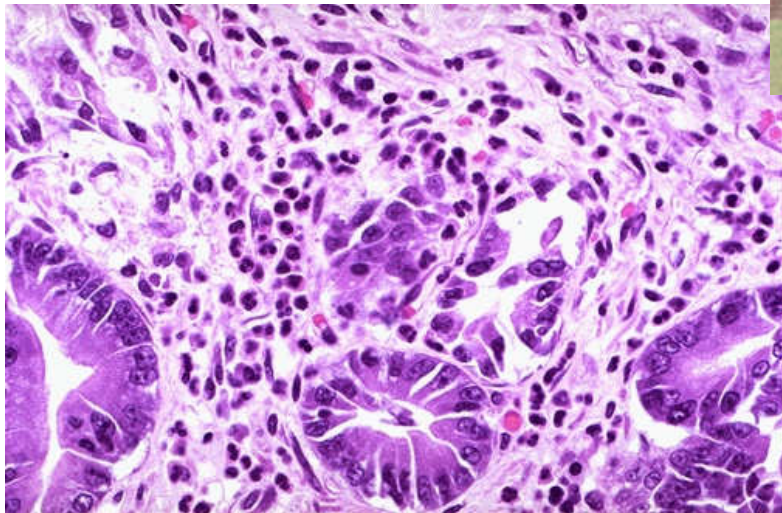
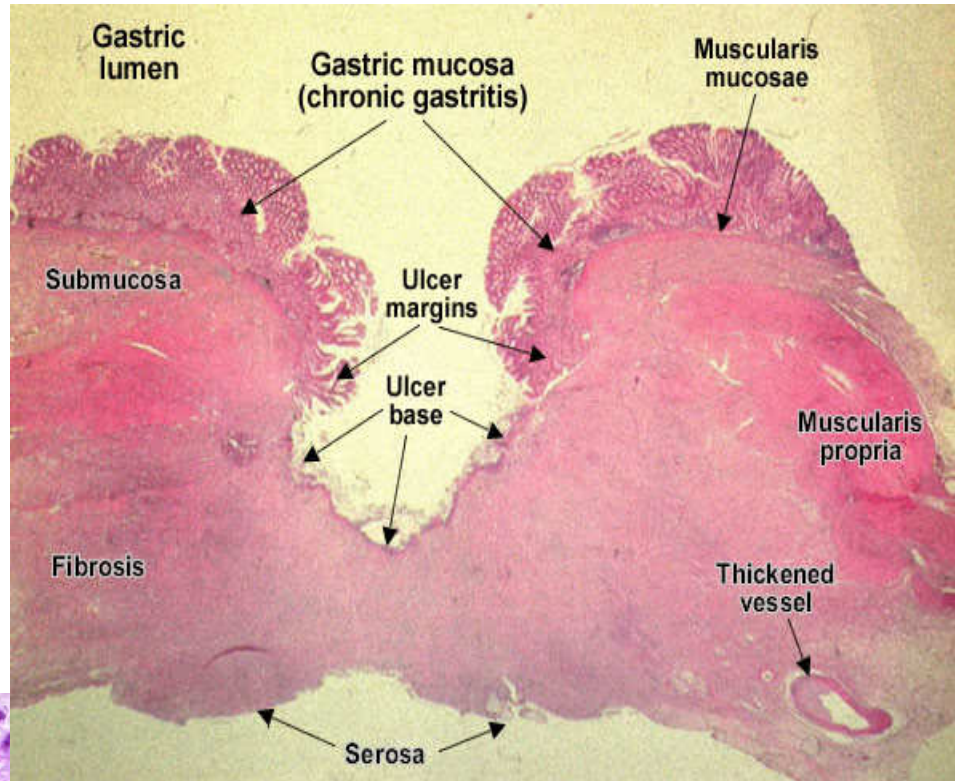
An acute duodenal ulcer is seen in two views on upper endoscopy in the panels below.



Here is a large 3 x 4 cm **gastric ulcer** that led to the resection of the stomach shown here. This ulcer is quite deep with irregular margins. Complications of gastric ulcers (either benign or malignant) include pain, bleeding, perforation, and obstruction



Peptic ulcer duodenum



On microscopic examination at high power, this gastric mucosa shows infiltration by **neutrophils**. This is acute gastritis

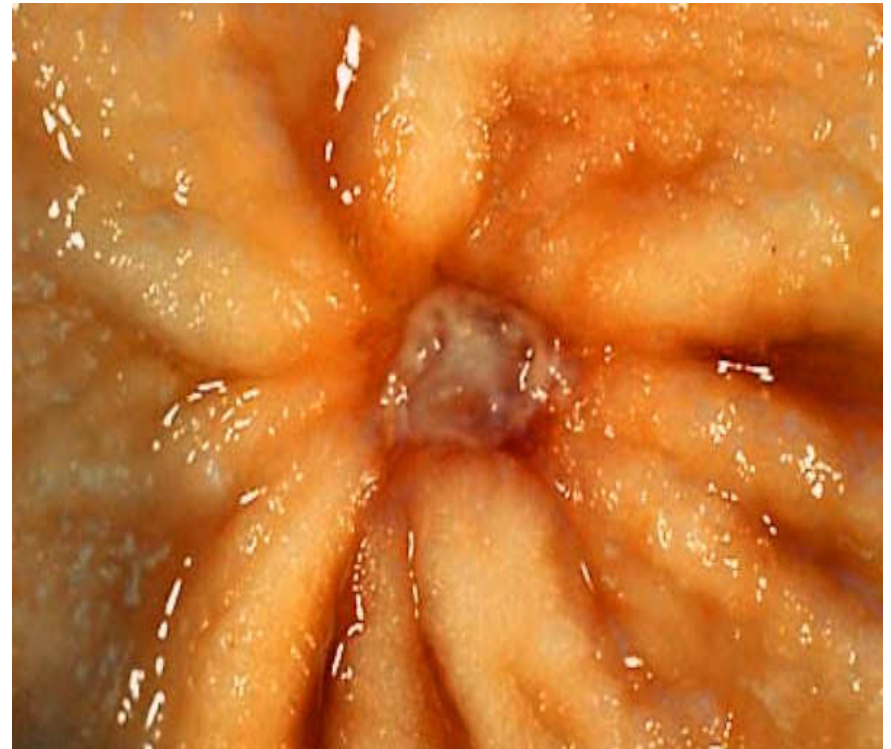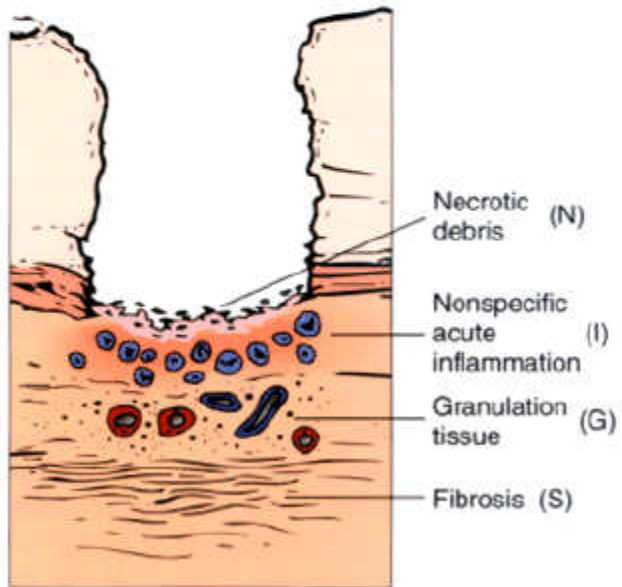
# Histological Features

- Varies from active necrosis to chronic inflammation & scarring to healing
- In active ulcers 4 zones can be recognised
  - Base & margins have thin layer of necrotic fibrinoid debris
  - Zone of non-specific inflammatory infiltrate (neutrophils predominate)
  - Active granulation tissue infiltrated with mononuclear leucocytes
  - Granulation tissue rests on fibrous/collagenous scar. Thickened vessel walls & thrombosed.



# Morphology

## PEPTIC ULCERATION



## The Base of a Non-perforated Chronic Peptic Ulcer

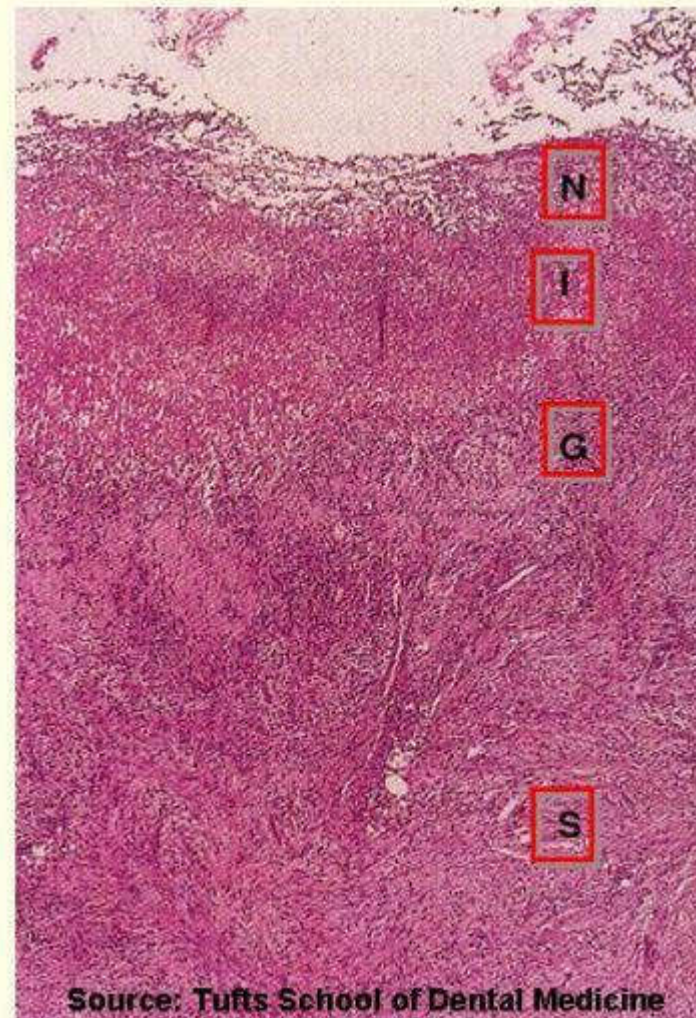
Necrosis (N)

Inflammation (I)

Granulation tissue (G)

Scar (S)

(Top - luminal surface,  
Bottom - muscular wall)



Source: Tufts School of Dental Medicine

(c) 2007, Michael A. Kahn, DDS/Lynn W. Solomon, DDS



# Histological Features

- Chronic gastritis is universal in pts with peptic ulcer
- Occur in 85-100% of pts with duodenal or gastric ulcers
- H.pylori is almost always demonstrable in pts with gastritis
- Gastritis can remain after ulcer has healed
- Recurrence of ulcer is not related to progression of gastritis
  - Helps distinguish peptic ulcer from acute erosive gastritis or stress ulcers which have normal adjacent mucosa

# Clinical Presentation

- Epigastric gnawing, burning or aching pain
- Anaemia, frank hemorrhage or perforation
- Pain
- Worse at night, 1-3 hrs after meals at daytime
- Pain relieved by alkalis or food
- Nausea, vomiting, bloating, belching or wt loss should raise suspicion occult malignancy
- Pain referred to back in penetrating ulcers, left upper quadrant or back
- Pain can be mistaken as being of cardiac origin
- Malena stool

# Treatment & Prognosis

- Notoriously chronic recurring lesions
- Impair quality of life more than shorten it
- Left untreated may take up to 15 years to heal
- Principles of treatment:
  - Reduce acid production
  - Promote mucus secretion
  - Neutralize acidity
  - H.pylori treatment

# Complications

- Bleeding
  - 15-20% of pts
  - Most frequent
  - Can be life threatening
  - Accounts for 25% of ulcer deaths
  - First indication of an ulcer
- Perforation
  - 5% of pts
  - Accounts for 66% of ulcer deaths
  - Late presentation
- Obstruction from oedema or scarring
  - 2% of pts
  - Occur in pyloric channel ulcers but can occur in duodenal ulcers
  - Chronic abdominal pain
- Chronic intractable pain

Acute peptic ulcer

# **ACUTE GASTRIC ULCERATION**

# Acute Gastric Ulceration

- Focal acutely developing gastric mucosal defects are well known complication of NSAIDs use
- Can occur after severe physiological stress hence name of stress ulcers
  - Pts with shock, extensive burns, sepsis or severe trauma or post intracranial surgery
- Generally multiple lesions mainly in stomach but can occur in duodenum
- Range in depth from superficial erosions to entire mucosal involvement (bona fide ulcer)
- Shallow erosions are extension of acute erosive gastritis
- Well defined ulcers are not precursors of chronic peptic ulcers

# Acute Gastric Ulceration

- Curling ulcers – patients with severe burns
  - Proximal duodenum
  - Associated with severe burns or trauma
- Cushing ulcers – intracranial injury, surgery or tumors
  - Stomach
  - Duodenum
  - Esophagus
  - Have high incidence of perforations

# Pathogenesis – Acute Gastric Ulcer

- Poorly understood
- Impaired oxygenation to mucosa may have role
- Cranial lesions – direct vagal stimulation by increase intracranial
  - Vagal stimulation causes increased acid secretion
- Systemic acidosis may contribute to mucosal compromise by lowering intracellular pH of mucosal cells already hypoxic by splanchnic vasoconstriction



# PATHOGENESIS OF PEPTIC ULCER

## AGGRESSIVE FORCES

1. *H. pylori* infection
2. NSAID, aspirin
3. Corticosteroids
4. Cigarette smoking
5. Alcohol

Imbalance between  
gastroduodenal mucosal  
defense forces and the  
aggressive forces.

## MUCOSAL DEFENSE FORCES

1. Surface mucus secretion
2. Bicarbonate secretion into mucus.
3. Mucosal blood flow
4. Apical epithelial cell transport system
5. Epithelial regenerative capacity
6. Elaboration of prostaglandin.

INCREASED GASTRIC  
ACIDITY AND PEPTIC  
ACTIVITY

IMPAIRED DEFENSES

GASTRIC ULCER

1. Ischemia, shock,  
stress related

2. Delayed gastric emptying

3. Duodenal- gastric reflux

DUODENAL ULCER

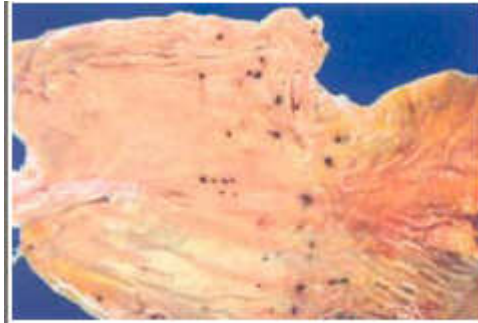4. Decreased retrograde motility impairs  
neutralization by pancreatic alkaline  
secretions

## ASSOCIATED DISEASES

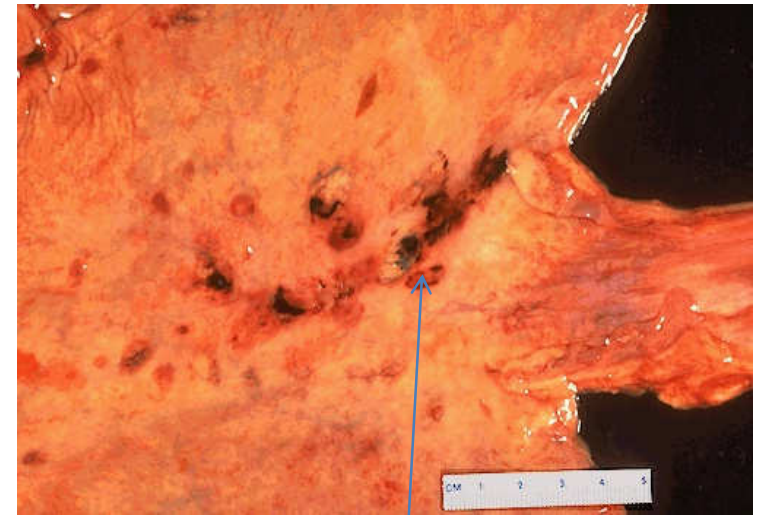
1. Cirrhosis
2. Chronic renal failure
3. Zollinger Ellison syndrome
4. Hyperparathyroidism
5. Chronic lung disease
6. Chronic pancreatitis.

# Morphology – Acute Gastric Ulcers

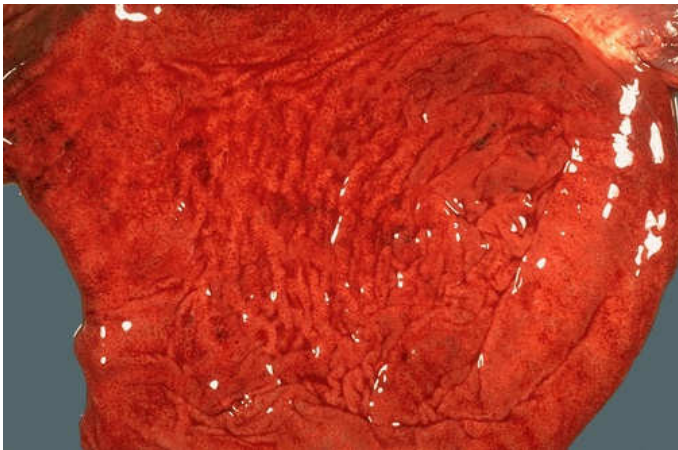
- <1cm, circular & small
- Multiple lesions is common
- Base is dark brown by acid digestion of extruded blood
- Occur anywhere in stomach
- Gastric rugal pattern is normal



Stress ulcers:  
multiple small  
ulcers. Digested  
blood appears dark  
on surface



Gastric  
hemorrhage &  
erosion



This is a more typical acute gastritis with a  
diffusely hyperemic gastric mucosa. There  
are many causes for acute gastritis:  
alcoholism, drugs, infections, etc.

# Histology – Acute Gastric Ulcers

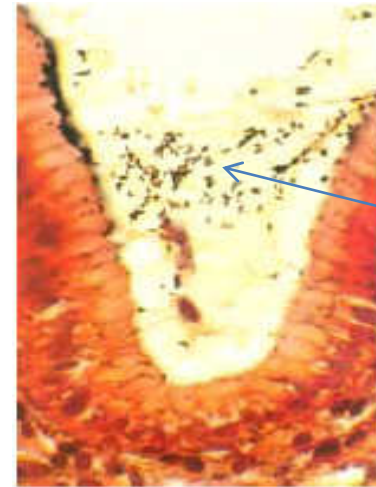- Abrupt lesions with unremarkable adjacent mucosa
- There may be suffusion of blood into mucosa & submucosa
- Some inflammatory reaction
- No scarring
- No thickening of blood vessels
- Complete healing occurs after treatment
  - Can heal in days to weeks.

# Clinical Presentation

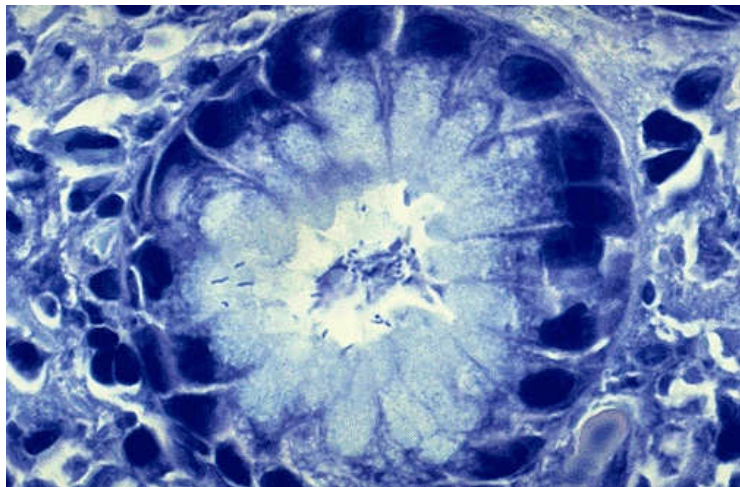
- 5-10% pts admitted to ICU units will develop gastric erosions acutely
- May be asymptomatic or severe enough to cause hemodynamic emergency
- Treatment is remove causative factors and treat primary illness
- Gastric mucosa will recover completely if managed well

# Diagnosis

- Gastroscopy & biopsy
- FBC
- Stool occult blood
- Barium meal



H.pylori  
Silver  
stain



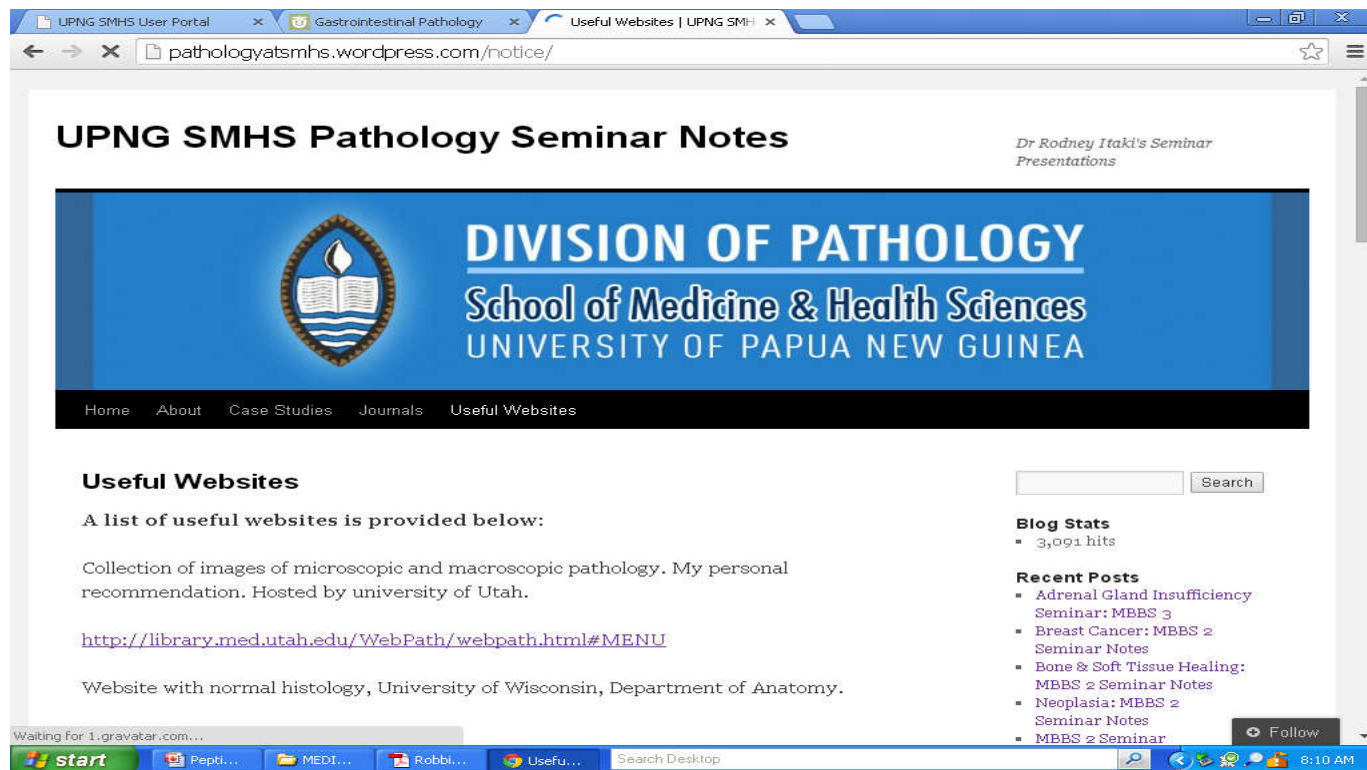
Chronic gastritis and peptic ulcer disease are often accompanied by infection with *Helicobacter pylori*. This small curved to spiral rod-shaped bacterium is found in the surface epithelial mucus of most patients with active gastritis. The **rod-shaped bacteria** are seen here with a **methylene blue stain**.



# END

## References: Robins Pathological Basis of Diseases

Download seminar notes: [www.pathologyatsmhs.wordpress.com](http://www.pathologyatsmhs.wordpress.com)



The screenshot shows a web browser window displaying the website [pathologyatsmhs.wordpress.com/notice/](http://pathologyatsmhs.wordpress.com/notice/). The page features a blue header with the text "UPNG SMHS Pathology Seminar Notes" and "Dr Rodney Itaki's Seminar Presentations". Below the header is a banner for the "DIVISION OF PATHOLOGY School of Medicine & Health Sciences UNIVERSITY OF PAPUA NEW GUINEA" with a logo of a book and a flame. The main content area includes a "Useful Websites" section with a list of links and a "Blog Stats" section showing 3,091 hits. The page also has a search bar and a "Follow" button.

UPNG SMHS Pathology Seminar Notes

*Dr Rodney Itaki's Seminar Presentations*

**DIVISION OF PATHOLOGY**  
School of Medicine & Health Sciences  
UNIVERSITY OF PAPUA NEW GUINEA

Home About Case Studies Journals Useful Websites

**Useful Websites**

A list of useful websites is provided below:

Collection of images of microscopic and macroscopic pathology. My personal recommendation. Hosted by university of Utah.

<http://library.med.utah.edu/WebPath/webpath.html#MENU>

Website with normal histology, University of Wisconsin, Department of Anatomy.

**Blog Stats**

- 3,091 hits

**Recent Posts**

- Adrenal Gland Insufficiency Seminar: MBBS 3
- Breast Cancer: MBBS 2 Seminar Notes
- Bone & Soft Tissue Healing: MBBS 2 Seminar Notes
- Neoplasia: MBBS 2 Seminar Notes
- MBBS 2 Seminar

Search

Follow